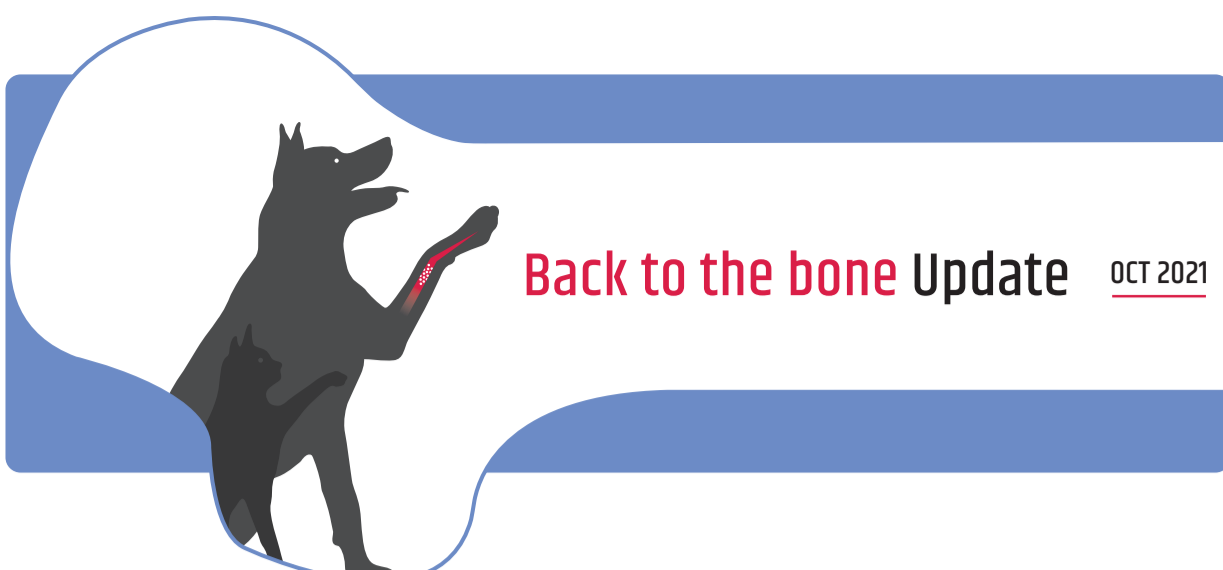



BIOCERA-VET BONE SURGERY – COMPARATIVE ANALYSIS VS. BONE AUTOGRAFT CLINICAL CASES REPORT IN THE INDICATION OF ARTHRODESIS

Year: 2021. Author: Céline Molle (TheraVet®). Collaborating Veterinary Surgeons: Dr Bernard Bouvy ECVS and ACVS, Clinique Vétérinaire Universitaire de Liège, Belgium. Dr Bernard Flasse, Centre Vétérinaire Beumont, Belgium. Dr Guillaume Ragetly ECVS and ACVS, Centre Hospitalier Vétérinaire Frégis, France. Dr Olivier Stiévenart, Surgivet, Belgium. Dr Johan Van Ommen, Dierenkliniek Orion, Belgium.

Materials & Methods

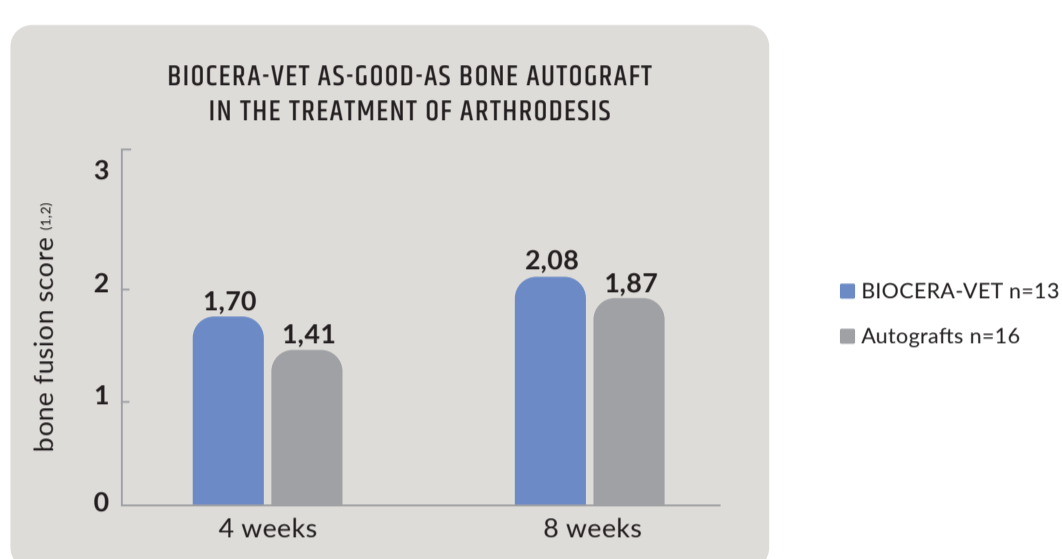
- ▶ BIOCERA-VET® injectable synthetic self-hardening calcium-phosphate bone substitute
- ▶ BIOCERA-VET (n=13) vs. autograft (n=16)
- ▶ Tarsal (BIOCERA-VET: n= 3 ; autograft: n=4) and carpal (BIOCERA-VET: n=10 ; autograft: n=12) arthrodesis
- ▶ Surgical procedure and clinical follow-up according to usual practice

Bone fusion was assessed by following an independent blinded radiological analysis performed by a qualified orthopedic surgeon using a numerical rating scale^{1,2} rating from

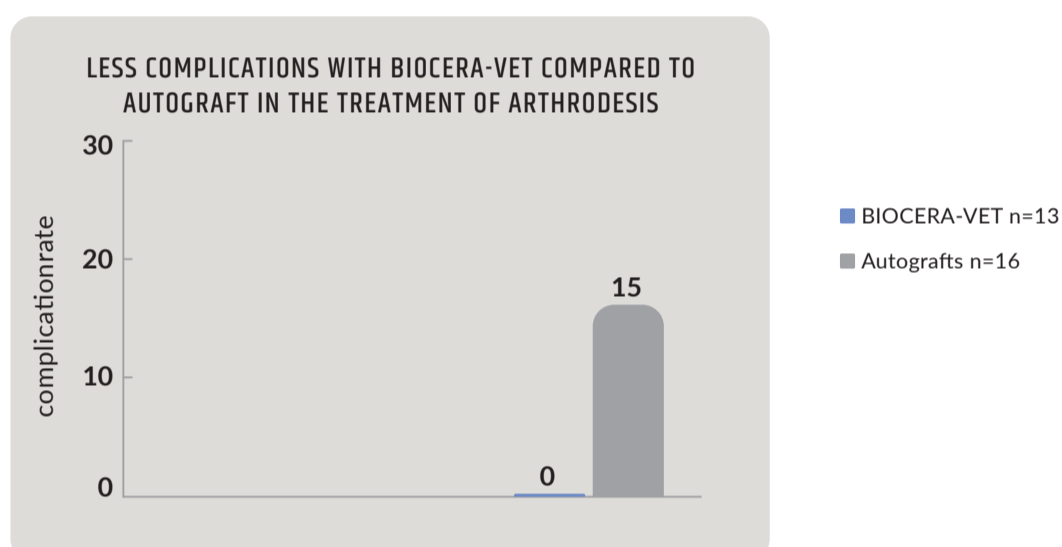
- ▶ 0: No mineralized (bone) tissue visible in the joint space;
- ▶ 1: Cancellous bone bridging the joint space, but joint space still clearly visible;
- ▶ 2: Bony bridging of joint space but subchondral bone plate still clearly visible;
- ▶ 3: Solid fusion of adjacent bones with modelling of bone and loss of subchondral bone plate.

Comparative analysis was performed at 4⁽³⁾ and 8⁽⁴⁾ weeks post-surgery.

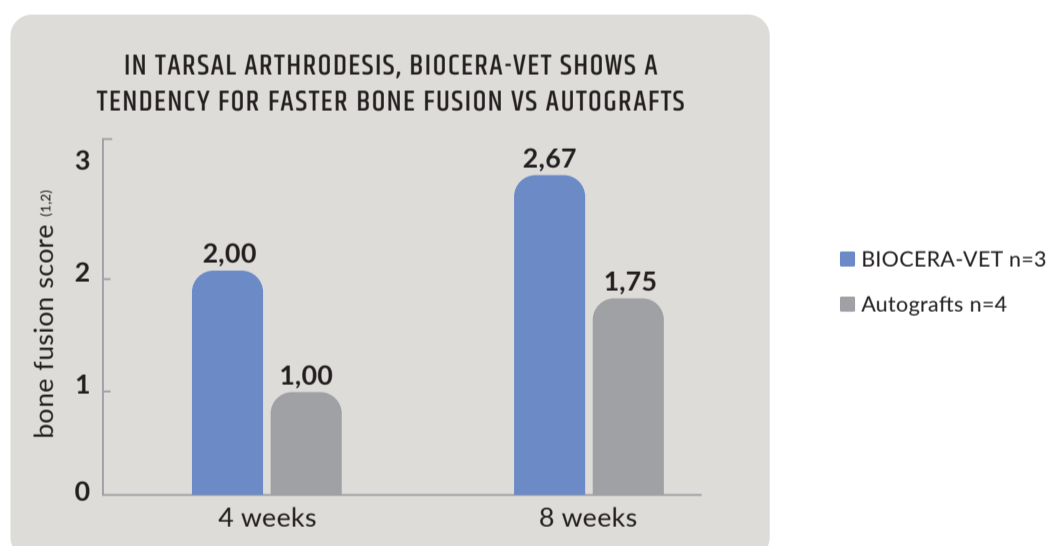
Results: Bone fusion induced by BIOCERA-VET was as-good-as the one induced by bone autograft.



No complication was reported in the 13 cases treated with BIOCERA-VET. The complication rate in the cases treated with autografts was similar to those reported in the literature, i.e. 15 to 30%^{5,6,7}.



In a smaller subgroup of pantarsal arthrodesis⁸, bone fusion induced by BIOCERA-VET was 50% more advanced than the one induced by bone autografts, although not reaching statistical significance. These observations suggest that BIOCERA-VET may accelerate the bone fusion process at tarsal level compared to autograft. This should be confirmed later on, in a larger comparative analysis.



Dr. Guillaume Ragetly
DMV, PhD, DipACVS,
DipECVS

Dr. Guillaume Ragetly, Head of Department of Surgery at CHV Frégis (France) : "BIOCERA-VET induces bone fusion thanks to its interesting properties of osteoconduction and osteointegration. It has real advantages for the veterinary surgeon allowing him to have an alternative to autograft, with less complications while saving significant surgical time".

CONCLUSION

- ▶ BIOCERA-VET shows a comparable efficacy to bone autograft in the treatment of arthrodesis with less complications
- ▶ In tarsal arthrodesis, BIOCERA-VET shows a tendency for faster bone fusion in comparison to autograft



BONE SURGERY 3cc

Indications

- ▶ Arthrodesis
- ▶ Fractures
- ▶ Corrective osteotomy
- ▶ TTA (Tibial Tuberosity Advancement)
- ▶ All indications for which bone grafts are required



BIOCERA-VET Bone Surgery available through www.thera.vet

1 Michal, U., Fluckiger, M., & Schmokelt, H. (2003). Healing of dorsal pancarpal arthrodesis in the dog. *Journal of Small Animal Practice*, 44(3), 109–112. 2 Jennifer J Ree, Wendy I Baltzer, Katy L Townsend, Augmentation of arthrodesis in dogs using a free autogenous omental graft. *Can Vet J*. 2016 Aug;57(8):835-41. 3 Radiological evaluation performed from 3 to 5 weeks post-surgery 4 Hoffer, MJ, Griffon, DJ, Schaeffer, DJ, Johnson, AL, & Thomas, MW (2008). Clinical Applications of Demineralized Bone Matrix: A Retrospective and Case-Matched Study of Seventy-Five Dogs. *Veterinary Surgery*, 37(7), 639–647 6 McKee WM, May C, Macias C, Lapish JP (2004) Pantarsal arthrodesis with a customised medial or lateral bone plate in 13 dogs. (2004). *Australian Veterinary Journal*, 82(12), 749–749. 7 Tuan, J., Comas, N., & Solano, M. (2019). Clinical outcomes and complications of pancarpal arthrodesis stabilised with 3.5 mm/2.7 mm locking compression plates with internal additional fixation in 12 dogs. *New Zealand Veterinary Journal*, 1–16. 8 Arthrodesis performed at tarsus